

# ESC Guidelines on the diagnosis and treatment of peripheral artery diseases

## Document covering atherosclerotic disease of extracranial carotid and vertebral, mesenteric, renal, upper and lower extremity arteries

### 7. Appendices

#### Appendix 1. Technical aspects of vascular imaging

##### Computed tomography angiography

The contrast agent for computed tomography angiography (CTA) is injected through a peripheral vein with an 18 G needle. The risks include the usual ones for contrast medium, particularly contrast allergy. Patient preparation for CTA is similar to that in other contrast-enhanced studies and includes the disclosure of information on contrast risks and an assessment of renal and thyroid function. A slice thickness of 1–3 mm is desirable for all CTAs. *Table 1* lists the main CTA parameters for imaging the great vessels.

Contrast administration has to be tailored to each patient to achieve optimum enhancement of the targeted vascular region, irrespective of whether the arterial or the venous phase appears important. Power injectors are needed with pre-defined flow rates of 3–5 mL/s. This is followed by injection of isotonic saline solution at the same rate. The saline flush provides rapid contrast medium inflow, keeps the bolus compact, and prolongs the plateau. If the complete vascular structures are imaged, a biphasic injection protocol can be followed. The initial injection includes 4 mL/s and the next 2–3 mL/s.

A test bolus injection is important, in order to assess the circulation time of the patient and to start the computed tomography (CT) data acquisition in time. Usually a bolus of 20 mL is used. Scans are taken at specific intervals, usually every 2 s. Many CT scanners have automated bolus triggering built into their systems, thereby avoiding the need for a test bolus.

For the imaging of peripheral arteries, electrocardiogram (ECG) gating or triggering is not necessary except for visualization of the supra-aortic vessels. Both prospective ECG triggering and retrospective ECG gating are possible.

CTAs are analysed interactively on the basis of the combination of axial images and post-processed views. The latter consist mainly of multiplanar reformatting and maximum intensity projections, which allow imaging according to an angiogram-like appearance. Special analytical software provides sectional images that are precisely orthogonal to the vessel axis and can be used for

quantification. The exact location and extent of abnormalities is determined with multiplanar use. Three-dimensional (3D) constructions using surface- or volume-rendering techniques help to depict complex 3D relationships and are helpful in the presentation of abnormalities. In addition, measurement of CT densities is helpful in the differentiation of tissue and vessel structures.<sup>1,2</sup>

##### Positron emission tomography/computed tomography

Modern imaging has developed to include a combination of different imaging techniques in order to provide information not only on vessel diameters and structures but also on metabolic or inflammatory processes. In more and more institutions the combination of positron emission tomography (PET) with multislice CT has become available. Very high resolution CT is used to identify the exact location of abnormalities, and [<sup>18</sup>F]fluorodeoxyglucose (FDG) is used to determine areas of inflammation.

CT images are acquired with 130 mA, 130 kV, a section width of 5 mm, and a table feed of 8 mm per rotation after defining the scanning area for CT and PET on a CT tomogram. Single-section whole-body spiral CT is performed, starting at the upper thigh and scanning in a caudocranial direction to the skull base, subsequently covering the pelvis, abdomen, chest, and neck, up to the base of the skull. A limited breath-hold technique is used to avoid motion-induced artefacts in the area of the diaphragm. Whole-body CT can be used for attenuation correction without the use of intravenous contrast material to avoid hardening artefacts in the mediastinum and to identify possible hyperdense intramural haematoma.

The PET system has an axial field of view of 15.5 cm per bed position and an in-plane spatial resolution of 4.6 mm. PET images cover the same field of view as the whole-body CT scan and are acquired 60 min after administration of 350 MBq of FDG. The tracer is chosen as the best-evaluated tracer in PET imaging to detect inflammation-induced elevated glucose metabolism.

Patients are instructed to fast for a minimum of 6 h prior to tracer injection. In addition, blood samples are collected immediately before the injection of the radioactive tracer to ensure blood glucose levels are within the normal range.

The acquisition time of PET is adapted according to the weight of the patient, using 3 min per bed position for patients up to

**Table 1** Scan parameters for CTA of the great vessels

<b>Scan volume</b>	
Thoracic aorta	Diaphragm up to and including the supra-aortic branches.
Pulmonary artery	Diaphragm to pulmonary apex. Pulmonary embolism: at least from the aortic arch to the diaphragmatic surface of the heart.
<b>Necessary views or planes</b>	Transverse slices; multiplanar reformatting if needed.
<b>Collimation</b>	≤3mm
<b>Slice thickness</b>	≤3mm
<b>Field of view</b>	Adapted to course of vessel.
<b>Matrix</b>	≥512
<b>Image acquisition / reconstruction</b>	Spiral technique is essential. ECG gating is obligatory only for imaging the aortic root; otherwise ECG is not essential
<b>Contrast medium</b>	Automated injection pump ( flow rate ≥2 mL/s) Intravascular enhancement ≥200 HU

CTA = computed tomography angiography; ECG = electrocardiogram.

65 kg, 4 min per bed position for patients up to 85 kg, and 5 min per bed position for patients weighing >85 kg. The FDG uptake is quantified as the maximal standardized uptake value (maximum SUV—correlated to body weight). CT data are used for attenuation correction of the PET images.

After the PET/CT scan an additional contrast-enhanced CT scan covering the chest and abdomen is obtained. For this, up to 120 mL of an iodinated contrast agent is administered according to a standardized protocol using an automated injector. Injection starts with a delay of 50 s for the first 70 mL with a flow rate of 3 mL/s. After that, the remaining 50 mL is administered with a flow rate of 1.5 mL/s.

The separate CT and PET data sets are afterwards accurately co-registered using special workstations.

## Magnetic resonance imaging

For magnetic resonance imaging (MRI), high-performance scanning is used with a high signal-to-noise ratio and rapid data acquisition. Morphological and functional studies require at least a 1.0 Tesla system. In recent years 3.0 Tesla systems have been employed for imaging, and 7 Tesla systems are used to study vessel wall structure. To increase the resolution, special phased-array surface coils are placed directly on the body, which provide a homogeneous magnetic field over a large area.

The first step in patient preparation is the explanation to the patient about the procedure and the assessment of all contraindications including cardiac pacemakers, implantable cardioverter defibrillators, neurostimulators, cochlear implants, and first-trimester pregnancy. Relative contraindications include claustrophobia, intracranial aneurysm, metallic foreign objects, and second- or

third-trimester pregnancy. Without intravenous contrast injection, time-of-flight angiography and phase-contrast angiography can be used to image the vascular bed. The problem is, however, that the intraluminal signal is dependent on complex flow effects. In addition, respiratory movements and cardiac motion in the chest lead to motion artefacts. T1-weighted 3D sequences were developed, acquiring a complete data set in <30 s. The sequences can be acquired during a single breath-hold. The heavy saturation of flowing spins requires the use of an effective T1-shortening contrast agent to produce an intraluminal signal that is very bright in comparison with the background.<sup>3–5</sup> The enhanced intraluminal signals are independent of flow phenomena, so that contrast-enhanced MRI reaches the diagnostic accuracy of digital subtraction angiography.

Different pulse sequences are available for image acquisition. Image contrast can be manipulated by varying the design and different variables of pulse sequences, including repetition time, echo time, and flip angle. The image contrast can also be varied by combining basic sequences with preparation pulses (fat saturation, inversion recovery, saturation recovery).

The speed of data acquisition depends critically on the performance of the gradient system. The goal is to shorten the repetition time and the echo time as much as possible. Partial Fourier techniques, zero filling, and parallel level imaging have become established techniques for accelerating data acquisition. Parallel imaging requires multiple coil elements for signal detection and a corresponding number of interconnectable receiver channels.

The standard pulse sequence for contrast-enhanced MRI is a spoiled 3D T1-weighted gradient echo sequence, which provides rapid imaging with acceptable resolution and coverage, enabling the images to be acquired during breath-holds. The 3D acquisition provides high resolution, with spatial resolution across the image plane and no breaks between the initial partitions.<sup>3</sup> A spoiled sequence is one in which all residual transverse magnetizations are destroyed before the next excitation. This increases the T1 weighting of the sequence and increases the contrast between the blood vessels and surrounding tissue.<sup>6</sup> The extracellular contrast agents that have been approved for clinical use are low-molecular weight hydrophilic gadolinium chelates such as the open-chain-complex gadolinium DTPA (Magnevist, Bayer Schering Pharma), gadodiamide (Omniscan, GE Amersham Buchler), and the neutral macrocyclic agent gadobutrol (Gadovist, Bayer Schering Pharma). These contrast agents shorten the T1 relaxation time of the blood to values between 30 and 80 ms.<sup>4,5</sup> It is sufficient to administer 0.1–0.15 mmol/kg or a total dose of 20 mL with acquisition times of 15–25 s.<sup>7,8</sup>

Currently, contrast agents have been developed that remain in the 'blood pool', which allows the examination of various regions without the need for additional contrast injections.

The current recommendations of the German Society of Radiology are listed in Table 2.

For successful contrast-enhanced magnetic resonance angiography (MRA) of the vessels, acquisition of the 3D data set should coincide with the arrival of the contrast bolus in the vessels of interest. Strategies for bolus timing include the test bolus measured as well as the manufacturer-specific automated or semi-automated techniques. The main advantage of the test bolus measured is that it does not require special hardware or software.

**Table 2** Imaging protocols for contrast-enhanced 3D MRA of the great vessels

Coil	Target-volume-adapted surface receiver coil system
Imaging volume	Thoracic aorta: diaphragm up to and including the supra-aortic vessels. Pulmonary arteries: diaphragm to the apex of the lung.
Slice location	Depends on the clinical question.
Scan parameters:	
Slice thickness	1.5–4 mm
FOV	≤480 mm
Maximum pixel size	≤1.9 × 2.7 mm <sup>2</sup>
Weighting sequences	T1, spoiled 3D gradient-echo sequence
Respiratory triggering	Breath-hold technique
ECG triggering	Optional; useful in investigations of the ascending aorta.
Intravenous contrast agent (Gd chelate)	0.1–0.2 mmol/kg body weight, injected at 2–4 mL/s
Additional requirements	Test bolus or bolus tracking. Analysis of source images and reconstruction.
Post processing	Optional: multiplanar reformatting, maximum intensity projection, volume rendering, subtraction.

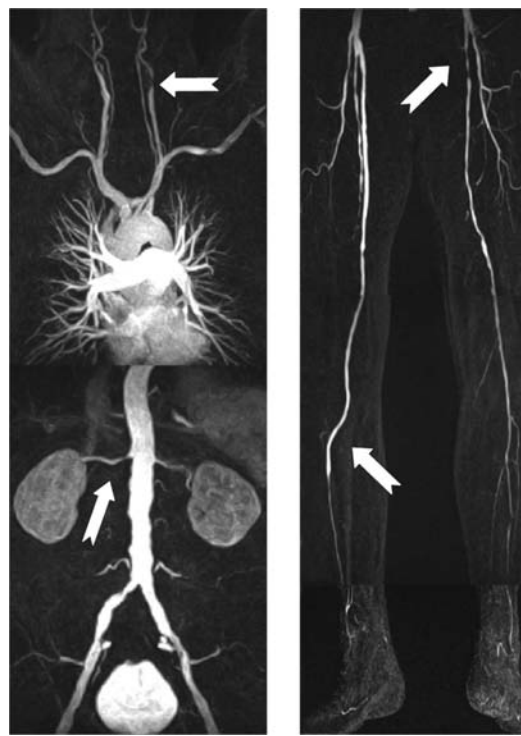ECG = electrocardiogram; FOV = field of view; MRA = magnetic resonance angiography.

A breakthrough for imaging has been the development of the 'Angiosurf' and 'Bodysurf' techniques.<sup>9,10</sup> The rolling platform with extended field of use allows a whole-body vessel examination without repositioning, which was previously necessary, in order to bring cranial and caudal body parts into the centre of the magnet in succession. An alternative is to cover the patient with coils, from the head to the toe, using several dozen simultaneous receiver channels and multiple plaques for attaching several radar frequency coils when a table range of 200 cm is available. The high number of simultaneous receiver channels allows parallel imaging.<sup>11</sup> The current craniocaudal field of view is limited to 40–50 cm depending on the homogeneity of the main magnetic field related to the length of the magnet and bore diameter.<sup>12</sup>

Based on the 'Angiosurf' MRA approach, a fairly comprehensive combined protocol can be used, which accomplishes the depiction of the head, thoracic, and all peripheral arteries from the carotids to the ankles (Figure 1).<sup>13,14</sup>

### The whole vessel and organ protocol

In order both to assess the vascular system and to detect organ damage, a special whole-body vessel and organ protocol has been developed.<sup>13</sup> Three different examination parts are used: the head, the heart, and the whole-body arteries. After pre-contrast imaging of the brain, whole-body MRA is acquired after intravenous contrast injection, using circular polarized head array coils and spin array coils integrated into the scanner table, as well as body array coils



**Figure 1** Magnetic resonance angiograms of a 66-year-old man, showing diffuse atherosclerosis, upper and lower extremity disease, carotid, and renal artery stenosis.

positioned anteriorly to the patient. Cardiac MRA is completed by cinematic imaging of myocardial contractility. In addition, a T1 sequence of the brain uses a contrast agent, which has to be applied. This step increases sensitivity for potential organ failure as well as helping to characterize consistent lesions. The time needed to conduct all three aspects of the examination is <40 min.<sup>12</sup>

## Appendix 2. Extracranial carotid and vertebral artery disease

### Measurement of carotid stenosis severity

Two different measurement techniques of internal carotid artery stenosis are shown in Figure 1. For the purpose of this document the NASCET criteria were used.

### Techniques of carotid endarterectomy Shunting

Temporary interruption of cerebral blood flow can cause neurological damage, which can be avoided by using a shunt and may also improve the outcome. Currently there is insufficient evidence from randomized controlled trials to support or refute the use of routine or selective shunting during carotid endarterectomy (CEA). There is also little evidence to promote one form of neurological monitoring over another in selecting patients who require a shunt during CEA.

### Patch angioplasty

Carotid patch angioplasty (either prosthetic or vein patch) may reduce the risk of carotid artery restenosis and subsequent ischaemic stroke when compared with CEA with primary closure. A Cochrane review included seven trials on this subject.<sup>16</sup> In general, the quality of the trials was poor. Carotid patch angioplasty was associated with a reduction in any type of stroke and a reduced risk of pre-operative arterial occlusion and decreased restenosis during follow-up. A more recent randomized trial confirmed the restenosis rate, but could not find any difference in the rate of perioperative complications.<sup>17</sup>

There has been no relevant evaluation between the use of selective patch angioplasty vs. primary angioplasty.

Among different studies, the differences between the outcomes with different patch materials are too small to draw any conclusion about which patch material is superior.

### Type of endarterectomy

Normally a CEA is performed using a longitudinal arteriotomy. Eversion CEA employs a transverse arteriotomy and reimplantation of the internal carotid artery on the common carotid artery. It is suggested that eversion CEA is associated with lower perioperative stroke and restenosis rates. In several trials there was no significant difference in stroke and death rate between eversion and conventional CEA techniques.

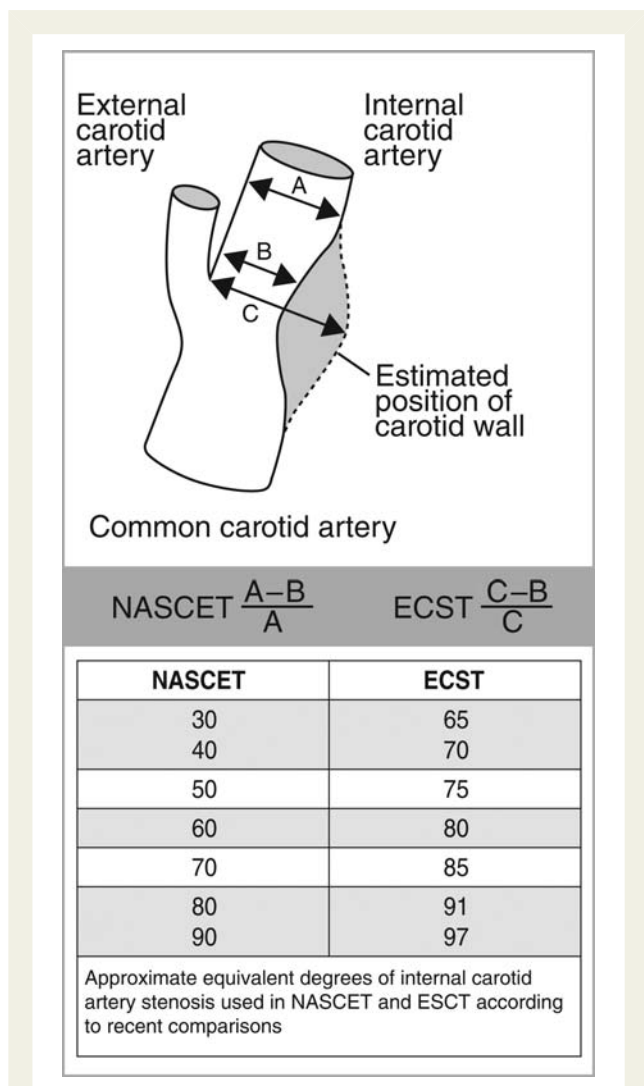
From a Cochrane analysis, it can be concluded that eversion CEA may be associated with lower risk of (sub)acute occlusion and restenosis.<sup>18</sup> Reduced restenosis rates were not associated with clinical benefit with regard to reduced stroke risk.

### Operator experience and outcomes in carotid artery stenting

Several single-centre experiences have described the impact of a learning curve for carotid artery stenting (CAS), with decreasing event rates over time.<sup>19–21</sup> In the Predictors of Death and Stroke in CAS (PRO-CAS) registry ( $n = 5341$ ), centres performing  $\leq 50$  CAS procedures per year had a complication rate of 4.6%, while those treating  $>50$  patients per year had an event rate of 2.9%. Centres with a total experience of 50, 51–150, and  $>150$  CAS procedures had death or stroke rates of 5.9, 4.5, and 3.0%, respectively. In multivariable analysis, a total CAS volume of 51–150 and of  $\leq 50$  cases were independently associated with an increased death or stroke rate when referred to the event rate of centres with a total experience of  $>150$  cases (ORs 1.77 and 1.48, respectively).<sup>22</sup>

With respect to the randomized CAS vs. CEA trials, the CARotid and Vertebral Artery Transluminal Angioplasty Study (CAVATAS) investigators described a marked decrease in event rates associated with endovascular carotid revascularization in the two centres with the greatest experience, with a stroke rate decreasing from 11% in the first 50 patients assigned to endovascular treatment to 4% in those treated subsequently.<sup>23</sup> While no information is available on total CAS centre or operator volume in the Stent-Protected Angioplasty versus Carotid Endarterectomy (SPACE) study, a significant increase in the CAS complication rate was observed with a decreasing number of patients enrolled in the endovascular arm per centre. The complication rates were 4.9, 9.4, and 12.1%, respectively, in centres enrolling  $\geq 25$  patients, 20–24 patients, and  $<20$  patients.<sup>24</sup>

In the Endarterectomy Versus Angioplasty in Patients with Symptomatic Severe Carotid Stenosis (EVA-3S) trial, no difference in outcomes was reported among patients treated by interventionists with a lifetime experience of  $>50$  CAS,  $<50$  CAS, and investigators-in-training. However, this analysis was limited by the fact that 45 out of 261 patients undergoing CAS in the trial were treated by operators with a lifetime experience of at least 50 CAS.<sup>25</sup> In the International Carotid Stenting Study (ICSS), non-supervised and supervised centres had similar event rates. However, investigators with a lifetime CAS experience of  $\geq 10$  CAS were able to treat patients with no supervision.<sup>26</sup> In addition, centres enrolling  $\geq 50$  patients had lower rates of CAS-related death, stroke, or myocardial infarction than centres with lower recruitment rates (11.0% vs. 7.1%).



**Figure 1** Differences between NASCET and ECST measurement techniques of internal carotid artery stenosis. Reproduced with permission from Donnan GA et al. *Lancet* 1989;**351**:1372–1373.<sup>15</sup>

So far, the best results for CAS in a randomized trial—for both symptomatic and asymptomatic patients—have been obtained in the Carotid Revascularization Endarterectomy vs. Stenting Trial (CREST), a study that mandated treatment of patients in a roll-in phase for centres with inadequate CAS experience.<sup>27</sup>

Overall, available evidence from single-centre experiences, registry data, and subgroup analyses from randomized trials support the notion that experience does play a major role in CAS outcomes. The benefit is probably conveyed by optimal procedure management and, equally important, appropriate patient selection.<sup>28</sup>

### Vertebral artery stenting

The prospective, multicentre Stenting of Symptomatic Atherosclerotic Lesions in the Vertebral or Intracranial Arteries (SSYLVIA) study enrolled 61 patients with vertebral artery (VA) disease, of whom 18 included the extracranial VA.<sup>29</sup> In this subgroup, two patients (11%) suffered a stroke at 1 year after stenting. Restenosis rates were high: six of 14 (43%) patients who underwent repeat angiography had a restenosis >50% at 6 months.

The largest series on extracranial VA stenting described 112 consecutive endovascular procedures in 105 symptomatic patients over a 12-year period. The procedure was performed almost exclusively with bare-metal stents in the absence of embolic protection device (EPDs). Technical success was 100%. Periprocedural complications included one flow-limiting dissection, two bleedings requiring transfusion, one access site complication, and one transient ischaemic attack (TIA).<sup>30</sup> No periprocedural stroke occurred. At 30 days, vertebrobasilar stroke occurred in two patients, and at 1 year in an additional three patients (total stroke rate at 1 year, 4.8%). While the restenosis rate was not reported, the rates of target vessel revascularization and sustained symptom resolution at a median follow-up of 29 months were 13% and 70%, respectively. It needs to be noted that there was no control group in this observational study.

Overall, multiple small series of stenting of extracranial VA stenoses reported a technical success of at least 95%; periprocedural stroke was absent in most of the series, occurring in <5% in all of them. Restenosis appears to be frequent after stenting in this vascular site. Its true incidence is unknown because the follow-up of most series was not systematic and the reported restenosis rate varied considerably (3–52%). Drug-eluting stents are being evaluated, but data on their use in the VA are still sparse.

## Appendix 3. Upper extremity artery disease

**Table 1** Differential diagnosis in upper limb ischaemia and arteries affected

Cause	Subclavian	Axillary	Brachial	Forearm	Hand
Atherosclerosis	•				
Thoracic outlet syndrome	•				
Giant cell arteritis	•	•	•		
Takayasu arteritis	•	•			
Radiation artery brosis	•	•			
Embolism		•	•	•	•
Fibromuscular dysplasia		•			•
Buerger's disease				•	•
Ergotism				•	•
Connective tissue disease				•	•
Cytotoxic drugs					•
Arterial drug injection					•
Diabetes					•
Myeloproliferative disorders					•
Hypercoagulation					•
Cryoglobulinemia					•
Repetitive trauma					•
Vinyl chloride exposure					•
Iatrogenic laesions	•	•	•	•	•

## Appendix 4. Renal artery disease

**Table 1** Pivotal controlled randomized trials and meta-analyses

Trial name/meta-analysis	Acronym	Authors	Journal/year	Outcome and remarks
Blood pressure outcome of angioplasty in atherosclerotic renal artery stenosis: a randomized trial	EMMA <sup>31</sup>	Plouin PF, Chatellier G, Darne B, et al.	<i>Hypertension</i> 1998	Primary EP: hypertension control. Result: trend towards better BP control after PTA. Limitation: Small numbers (23 patients in drug arm vs. 26 in PTA arm).
Randomized comparison of percutaneous angioplasty vs continued medical therapy for hypertensive patients with atheromatous renal artery stenosis	SNRASC <sup>32</sup>	Webster J, Marshall F, Abdalla M, et al.	<i>J Hum Hypertens</i> 1998	Primary EP: hypertension control. Result: difference in BP was 26/10 mmHg in favour of PTA ( $P=ns$ ). Subgroup of bilateral RAS: sign. BP drop in PTA group ( $P<0.05$ ). Limitations: small study cohort (55 patients), stenoses >50% included.
Arterial stenting and balloon angioplasty in ostial atherosclerotic renovascular disease: a randomized trial <sup>33</sup>		Van de Ven PJG, Kaatee R, Beutler JJ, et al.	<i>Lancet</i> 1999	Technical success: 57% (PTA) vs. 88% (stent). Restenosis rate: 48% (PTA) vs. 14% (stent).
The Effect of Balloon Angioplasty on Hypertension in Atherosclerotic Renal-Artery Stenosis	DRASTIC <sup>34</sup>	Van Jaarsveld BC, Krijnen P, Pieterman H, et al.	<i>N Engl J Med</i> 2000	Primary EP: difference in BP response at 12 years. Result: mean daily drug dose significantly lower in the angioplasty group ( $2.1 \pm 1.3$ vs. $3.2 \pm 1.5$ , $P<0.001$ ). No difference in BP control. Limitation: interpretation hampered by 44% crossover rate to balloon angioplasty (44%) in the drug group.
Revascularization versus medical therapy for renal artery stenosis	ASTRAL <sup>35</sup>	Wheatley K, Ives N, Gray R et al.	<i>N Engl J Med</i> 2009	No evidence for clinically important benefit from revascularization in patients with atherosclerotic renovascular disease.
Balloon angioplasty or medical therapy for hypertensive patients with atherosclerotic renal artery stenosis? A meta-analysis of randomized controlled trials. <sup>36</sup>		Nordmann AJ, Woo K, Parkes R, Logan AG	<i>Am J Med</i> 2003	Pooled analysis of DRASTIC, EMMA, and SNRASC (206 patients overall). Result: significantly better systolic and diastolic BP after PTA.
The benefit of Stent placement and blood pressure and lipid-lowering for the prevention of progression of renal dysfunction caused by Atherosclerotic ostial stenosis of the Renal artery	STAR <sup>37</sup>	Bax L, Woittiez AJ, Kouwenberg HJ, Mali PTM, Buskens E, et al.	<i>Ann Intern Med</i> 2009;16:150:840-8, W150-1. Epub 2009 May 4.	Primary EP: reduction in creatinine clearance >20% compared with baseline. 140 patients followed-up for 2 years with extended follow-up to 5 years. Result: 16% in stent group and 20% in medication group reached the primary EP. Limitations: the study was underpowered to provide a definitive estimate of efficacy. Only 46/64 patients assigned to stenting received a stent.
Prospective randomized trial of operative vs interventional treatment for renal artery ostial occlusive disease	RAOOD <sup>38</sup>	Balzer KM, Pfeiffer T, Rossbach S, Voiculescu A, Milder U, Godehardt E, Sandmann W	<i>J Vasc Surg</i> 2009;49:667-74	Single-centre study. Primary EP: composite of complications and durability. Fifty patients (25 per group) with RAS >70% with follow-up >4 years. Results: procedure-related morbidity was 13% in interventional group and 4% in surgical group. Four-year follow-up mortality was 18% in interventional group and 25% in surgical group. Both groups showed significant improvement in blood pressure ( $P<0.001$ in each group) and improvement in or stabilization of renal function. Freedom from recurrent RAS (>70%) was achieved in 90.1% of surgical group and 79.9% of interventional group.

BP = blood pressure; EP = endpoint; GFR = glomerular filtration rate; NS = not significant; PTA = percutaneous transluminal angioplasty; RAS = renal artery stenosis.

## Appendix 5. Multisite artery disease

**Table 1** Summary of 30-day clinical results of associated CEA and CABG in recently published papers

Study	n	Pts/year	Death (%)	Stroke (%)	MI (%)	Death/stroke (%)
Naylor R <i>et al.</i> <sup>39</sup>	7863	-	4.5	4.5	3.9	8.4
Kolh PH <i>et al.</i> <sup>40</sup>	311	22	6.1	5.5	2.2	11.6
Hill MD <i>et al.</i> <sup>41</sup>	669	-	4.9	8.5	-	13.0
Brown KR <i>et al.</i> <sup>42</sup>	226	-	6.6	12	-	17.7
Dubinsky PM and Lai SM <sup>43</sup>	7073	-	5.6	4.9	-	9.7
Byrne J <i>et al.</i> <sup>44</sup>	702	28	-	-	-	4.4
Kougias P <i>et al.</i> <sup>45</sup>	277	12	3.6	2.8	0.7	7.4
Char D <i>et al.</i> <sup>46</sup>	154	26	3.9	3.9	-	7.8
Cywinski JB <i>et al.</i> <sup>47</sup>	272	25	5.2	5.2	2.9	12.4
Ricotta JJ <i>et al.</i> <sup>48</sup>	744	-	4.4	5.1	-	8.1
Timaran CH <i>et al.</i> <sup>49</sup>	26,197	-	5.4	3.9	-	8.6

CABG = coronary artery bypass graft; CEA = carotid endarterectomy; MI = myocardial infarction; Pts/year = average number of patients treated per year at a single centre

**Table 2** Summary of 30-day clinical results of staged or simultaneous CAS and CABG in recently published papers

Study	n	Pts/year	Death (%)	Stroke (%)	MI (%)	Death/stroke (%)	EPD (%)	CABG timing
Ziada KM <i>et al.</i> <sup>50</sup>	56	10	5.4	1.8	3.3	7.1	14	Staged
Kovacic JC <i>et al.</i> <sup>51</sup>	20	-	0	5	5	5.0	38	Staged
Randall MS <i>et al.</i> <sup>52</sup>	52	7	13.5	5.8	-	-	69	Staged
Mendiz O <i>et al.</i> <sup>53</sup>	30	3	10	0	3.3	10.0	42	Simultaneous
Versaci F <i>et al.</i> <sup>54</sup>	101	15	2.0	2.0	0	4.0	100	Simultaneous
Van der Heyden J <i>et al.</i> <sup>55</sup>	356	47	3.7	3.1	2	4.8	40	Staged
Timaran CH <i>et al.</i> <sup>49</sup>	887	0	5.2	2.4	-	6.9	-	-

CABG = coronary artery bypass graft; CAS = carotid artery stenting; EPD = use of embolic protection devices; MI = myocardial infarction; Pts/year = average number of patients treated per year at a single centre.

**Table 3** Time course of adverse events in staged CAS followed by CABG

Study	n	After CAS, prior to CABG (%)			After CABG (%)			Total (%)
		Death	Stroke	MI	Death	Stroke	MI	Death/stroke/MI
Ziada KM <i>et al.</i> <sup>50</sup>	111	3.6	1.8	0	1.8	0	3.6	7.1
Kovacic JC <i>et al.</i> <sup>51</sup>	23	0	5	0	0	0	5	5.0
Randall MS <i>et al.</i> <sup>52</sup>	51	5.8	0	1.9	7.7	5.8	-	19.2
Van der Heyden J <i>et al.</i> <sup>55</sup>	356	0.3	1.4	0.6	3.4	1.7	1.4	4.8

CAS = carotid artery stenting; CABG = coronary artery bypass graft; MI = myocardial infarction

## References for Appendices

- Quinn SF, Sheley RC, Semonsen KG, Leonardo VJ, Kojima K, Szumowski J. Aortic and lower-extremity arterial disease: evaluation with MR angiography versus conventional angiography. *Radiology* 1998;**206**:693–701.
- Nelermans PJ, Leiner T, de Vet HC, van Engelshoven JM. Peripheral arterial disease: meta-analysis of the diagnostic performance of MR angiography. *Radiology* 2000;**217**:105–114.
- Barnes RW. Noninvasive diagnostic assessment of peripheral vascular disease. *Circulation* 1991;**83**:120–127.
- Maki JH, Prince MR, Chenevert TC. Optimizing three-dimensional gadolinium-enhanced magnetic resonance angiography. Original investigation. *Invest Radiol* 1998;**33**:528–537.
- Saloner D. Determinants of image appearance in contrast-enhanced magnetic resonance angiography. A review. *Invest Radiol* 1998;**33**:488–495.
- Clement DL, Van Maele GO, De Pue NY. Critical evaluation of venous occlusion plethysmography in the diagnosis of occlusive arterial diseases in the lower limbs. *Int Angiol* 1985;**4**:69–74.
- Watson L, Ellis B, Leng GC. Exercise for intermittent claudication. *Cochrane Database Syst Rev* 2008;**4**:CD000990.
- Gardner AW, Poehlman ET. Exercise rehabilitation programs for the treatment of claudication pain. A meta-analysis. *JAMA* 1995;**274**:975–980.
- Ruehm SG, Goyen M, Barkhausen J, Kroger K, Bosk S, Ladd ME, Debatin JF. Rapid magnetic resonance angiography for detection of atherosclerosis. *Lancet* 2001;**357**:1086–1091.
- Goyen M, Quick HH, Debatin JF, Ladd ME, Barkhausen J, Herborn CU, Bosk S, Kuehl H, Schlepütz M, Ruehm SG. Whole-body three-dimensional MR angiography with a rolling table platform: initial clinical experience. *Radiology* 2002;**224**:270–277.
- Hiatt WR, Wolfel EE, Meier RH, Regensteiner JG. Superiority of treadmill walking exercise versus strength training for patients with peripheral arterial disease. Implications for the mechanism of the training response. *Circulation* 1994;**90**:1866–1874.
- Hodges LD, Sandercock GR, Das SK, Brodie DA. Randomized controlled trial of supervised exercise to evaluate changes in cardiac function in patients with peripheral atherosclerotic disease. *Clin Physiol Funct Imaging* 2008;**28**:32–37.
- Gohde SC, Goyen M, Forsting M, Debatin JF. [Prevention without radiation—a strategy for comprehensive early detection using magnetic resonance tomography]. *Radiologe* 2002;**42**:622–629.
- Fenchel M, Scheule AM, Stauder NI, Kramer U, Tomaschko K, Nagele T, Bretschneider C, Schlemmer HP, Claussen CD, Miller S. Atherosclerotic disease: whole-body cardiovascular imaging with MR system with 32 receiver channels and total-body surface coil technology—initial clinical results. *Radiology* 2006;**238**:280–291.
- Donnan GA, Davis SM, Chambers BR, Gates PC. Surgery for prevention of stroke. *Lancet* 1998;**351**:1372–1373.
- Bond R, Rerkasem K, AbuRahma AF, Naylor AR, Rothwell PM. Patch angioplasty versus primary closure for carotid endarterectomy. *Cochrane Database Syst Rev* 2004;**2**:CD000160.
- Mannheim D, Weller B, Vahadim E, Karmeli R. Carotid endarterectomy with a polyurethane patch versus primary closure: a prospective randomized study. *J Vasc Surg* 2005;**41**:403–407; discussion 407–408.
- Cao PG, de Rango P, Zannetti S, Giordano G, Ricci S, Celani MG. Eversion versus conventional carotid endarterectomy for preventing stroke. *Cochrane Database Syst Rev* 2001;**1**:CD001921.
- Ahmadi R, Willfort A, Lang W, Schillinger M, Alt E, Gschwandtner ME, Haumer M, Maca T, Ehringer H, Minar E. Carotid artery stenting: effect of learning curve and intermediate-term morphological outcome. *J Endovasc Ther* 2001;**8**:539–546.
- Verzini F, Cao P, De Rango P, Parlani G, Maselli A, Romano L, Norgiolini L, Giordano G. Appropriateness of learning curve for carotid artery stenting: an analysis of periprocedural complications. *J Vasc Surg* 2006;**44**:1205–1211; discussion 1211–1202.
- Lin PH, Bush RL, Peden EK, Zhou W, Guerrero M, Henao EA, Kougias P, Mohiuddin I, Lumsden AB. Carotid artery stenting with neuroprotection: assessing the learning curve and treatment outcome. *Am J Surg* 2005;**190**:850–857.
- Theiss W, Hermanek P, Mathias K, Bruckmann H, Dembski J, Hoffmann FJ, Kerner R, Leisch F, Mudra H, Schulte KL, Sievert H. Predictors of death and stroke after carotid angioplasty and stenting: a subgroup analysis of the Pro-CAS data. *Stroke* 2008;**39**:2325–2330.
- Endovascular versus surgical treatment in patients with carotid stenosis in the Carotid and Vertebral Artery Transluminal Angioplasty Study (CAVATAS): a randomised trial. *Lancet* 2001;**357**:1729–1737.
- Fiehler J, Jansen O, Berger J, Eckstein HH, Ringleb PA, Stिंगele R. Differences in complication rates among the centres in the SPACE study. *Neuroradiology* 2008;**50**:1049–1053.
- Mas JL, Chatellier G, Beyssen B, Branchereau A, Moulin T, Becquemin JP, Larrue V, Lievre M, Leys D, Bonneville JF, Watelet J, Pruvo JP, Albuquer JF, Viguier A, Piquet P, Garnier P, Viader F, Touze E, Giroud M, Hosseini H, Pillet JC, Favrole P, Neau JP, Ducrocq X. Endarterectomy versus stenting in patients with symptomatic severe carotid stenosis. *N Engl J Med* 2006;**355**:1660–1671.
- Ederle J, Dobson J, Featherstone RL, Bonati LH, van der Worp HB, de Borst GJ, Lo TH, Gaines P, Dorman PJ, Macdonald S, Lyrer PA, Hendriks JM, McCollum C, Nederkoorn PJ, Brown MM. Carotid artery stenting compared with endarterectomy in patients with symptomatic carotid stenosis (International Carotid Stenting Study): an interim analysis of a randomised controlled trial. *Lancet* 2010;**375**:985–997.
- Brott TG, Hobson RW 2nd, Howard G, Roubin GS, Clark WM, Brooks W, Mackey A, Hill MD, Leimgruber PP, Sheffet AJ, Howard VJ, Moore WS, Voeks JH, Hopkins LN, Cutlip DE, Cohen DJ, Popma JJ, Ferguson RD, Cohen SN, Blackshear JL, Silver FL, Mohr JP, Lal BK, Meschia JF. Stenting versus endarterectomy for treatment of carotid-artery stenosis. *N Engl J Med* 2010;**363**:11–23.
- Roffi M, Sievert H, Gray WA, White CJ, Torsello G, Cao P, Reimers B, Mathias K, Setacci S, Schonholz C, Clair DG, Schillinger M, Grunwald I, Bosiers M, Abou-Chebl A, Moussa ID, Mudra H, Iyer SS, Scheinert D, Yadav JS, van Sambeek MR, Holmes DR, Cremonesi A. Carotid artery stenting versus surgery: adequate comparisons? *Lancet Neurol* 2010;**9**:339–341.
- SSYLVA Study Investigators. Stenting of Symptomatic Atherosclerotic Lesions in the Vertebral or Intracranial Arteries (SSYLVA): study results. *Stroke* 2004;**35**:1388–1392.
- Jenkins JS, Patel SN, White CJ, Collins TJ, Reilly JP, McMullan PW, Grise MA, Grant AG, Ramee SR. Endovascular stenting for vertebral artery stenosis. *J Am Coll Cardiol* 2010;**55**:538–542.
- Plouin PF, Chatellier G, Darne B, Raynaud A. Blood pressure outcome of angioplasty in atherosclerotic renal artery stenosis: a randomized trial. Essai Multicentrique Medicaments vs Angioplastie (EMMA) Study Group. *Hypertension* 1998;**31**:823–829.
- Webster J, Marshall F, Abdalla M, Dominiczak A, Edwards R, Isles CG, Loose H, Main J, Padfield P, Russell IT, Walker B, Watson M, Wilkinson R. Randomised comparison of percutaneous angioplasty vs continued medical therapy for hypertensive patients with atheromatous renal artery stenosis. Scottish and Newcastle Renal Artery Stenosis Collaborative Group. *J Hum Hypertens* 1998;**12**:329–335.
- van de Ven PJ, Kaatee R, Beutler JJ, Beek FJ, Woittiez AJ, Buskens E, Koomans HA, Mali WP. Arterial stenting and balloon angioplasty in ostial atherosclerotic renovascular disease: a randomised trial. *Lancet* 1999;**353**:282–286.
- van Jaarsveld BC, Krijnen P, Pieterman H, Derckx FH, Deinum J, Postma CT, Dees A, Woittiez AJ, Bartelink AK, Man in 't Veld AJ, Schalekamp MA. The effect of balloon angioplasty on hypertension in atherosclerotic renal-artery stenosis. Dutch Renal Artery Stenosis Intervention Cooperative Study Group. *N Engl J Med* 2000;**342**:1007–1014.
- Wheatley K, Ives N, Gray R, Kalra PA, Moss JG, Baigent C, Carr S, Chalmers N, Eadington D, Hamilton G, Lipkin G, Nicholson A, Scoble J. Revascularization versus medical therapy for renal-artery stenosis. *N Engl J Med* 2009;**361**:1953–1962.
- Schwarzwalder U, Hauk M, Zeller T. RADAR—a randomised, multi-centre, prospective study comparing best medical treatment versus best medical treatment plus renal artery stenting in patients with haemodynamically relevant atherosclerotic renal artery stenosis. *Trials* 2009;**10**:60.
- Bax L, Woittiez AJ, Kouwenberg HJ, Mali WP, Buskens E, Beek FJ, Braam B, Huysmans FT, Schultze Kool LJ, Rutten MJ, Doorenbos CJ, Aarts JC, Rabelink TJ, Plouin PF, Raynaud A, van Montfrans GA, Reekers JA, van den Meiracker AH, Pattynama PM, van de Ven PJ, Vroegindeweij D, Kroon AA, de Haan MW, Postma CT, Beutler JJ. Stent placement in patients with atherosclerotic renal artery stenosis and impaired renal function: a randomized trial. *Ann Intern Med* 2009;**150**:840–848, W150–W151.
- Balzer KM, Pfeiffer T, Rossbach S, Voiculescu A, Modder U, Godehardt E, Sandmann W. Prospective randomized trial of operative vs interventional treatment for renal artery ostial occlusive disease (RAOOD). *J Vasc Surg* 2009;**49**:667–674; discussion 674–665.
- Naylor R, Cuffe RL, Rothwell PM, Loftus IM, Bell PR. A systematic review of outcome following synchronous carotid endarterectomy and coronary artery bypass: influence of surgical and patient variables. *Eur J Vasc Endovasc Surg* 2003;**26**:230–241.
- Kolh PH, Comte L, Tchana-Sato V, Honore C, Kerzmann A, Mauer M, Limet R. Concurrent coronary and carotid artery surgery: factors influencing perioperative outcome and long-term results. *Eur Heart J* 2006;**27**:49–56.
- Hill MD, Shrive FM, Kennedy J, Feasby TE, Ghali WA. Simultaneous carotid endarterectomy and coronary artery bypass surgery in Canada. *Neurology* 2005;**64**:1435–1437.



42. Brown KR, Kresowik TF, Chin MH, Kresowik RA, Grund SL, Hendel ME. Multi-state population-based outcomes of combined carotid endarterectomy and coronary artery bypass. *J Vasc Surg* 2003;**37**:32–39.
43. Dubinsky RM, Lai SM. Mortality from combined carotid endarterectomy and coronary artery bypass surgery in the US. *Neurology* 2007;**68**:195–197.
44. Byrne J, Darling RC 3rd, Roddy SP, Mehta M, Paty PS, Kreienberg PB, Chang BB, Ozsvath KJ, Shah DM. Combined carotid endarterectomy and coronary artery bypass grafting in patients with asymptomatic high-grade stenoses: an analysis of 758 procedures. *J Vasc Surg* 2006;**44**:67–72.
45. Kougias P, Kappa JR, Sewell DH, Feit RA, Michalik RE, Imam M, Greenfield TD. Simultaneous carotid endarterectomy and coronary artery bypass grafting: results in specific patient groups. *Ann Vasc Surg* 2007;**21**:408–414.
46. Char D, Cuadra S, Ricotta J, Bilfinger T, Giron F, McLarty A, Krukenkamp I, Saltman A, Seifert F. Combined coronary artery bypass and carotid endarterectomy: long-term results. *Cardiovasc Surg* 2002;**10**:111–115.
47. Cywinski JB, Koch CG, Krajewski LP, Smedira N, Li L, Starr NJ. Increased risk associated with combined carotid endarterectomy and coronary artery bypass graft surgery: a propensity-matched comparison with isolated coronary artery bypass graft surgery. *J Cardiothorac Vasc Anesth* 2006;**20**:796–802.
48. Ricotta JJ, Wall LP, Blackstone E. The influence of concurrent carotid endarterectomy on coronary bypass: a case-controlled study. *J Vasc Surg* 2005;**41**:397–401; discussion 401–392.
49. Timaran CH, Rosero EB, Smith ST, Valentine RJ, Modrall JG, Clagett GP. Trends and outcomes of concurrent carotid revascularization and coronary bypass. *J Vasc Surg* 2008;**48**:355–361. e351.
50. Ziada KM, Yadav JS, Mukherjee D, Lauer MS, Bhatt DL, Kapadia S, Roffi M, Vora N, Tiong I, Bajzer C. Comparison of results of carotid stenting followed by open heart surgery versus combined carotid endarterectomy and open heart surgery (coronary bypass with or without another procedure). *Am J Cardiol* 2005;**96**:519–523.
51. Kovacic JC, Roy PR, Baron DW, Muller DW. Staged carotid artery stenting and coronary artery bypass graft surgery: initial results from a single center. *Catheter Cardiovasc Interv* 2006;**67**:142–148.
52. Randall MS, McKeivitt FM, Cleveland TJ, Gaines PA, Venables GS. Is there any benefit from staged carotid and coronary revascularization using carotid stents? A single-center experience highlights the need for a randomized controlled trial. *Stroke* 2006;**37**:435–439.
53. Mendiz O, Fava C, Valdivieso L, Dulbecco E, Raffaelli H, Lev G, Favaloro R. Synchronous carotid stenting and cardiac surgery: an initial single-center experience. *Catheter Cardiovasc Interv* 2006;**68**:424–428.
54. Versaci F, Reimers B, Del Giudice C, Schofer J, Giacomini A, Sacca S, Gandini R, Albiero R, Pellegrino A, Bertoldo F, Simonetti G, Chiariello L. Simultaneous hybrid revascularization by carotid stenting and coronary artery bypass grafting: the SHARP study. *JACC Cardiovasc Interv* 2009;**2**:393–401.
55. Van der Heyden J, Suttorp MJ, Bal ET, Ernst JM, Ackerstaff RG, Schaap J, Kelder JC, Schepens M, Plokker HW. Staged carotid angioplasty and stenting followed by cardiac surgery in patients with severe asymptomatic carotid artery stenosis: early and long-term results. *Circulation* 2007;**116**:2036–2042.